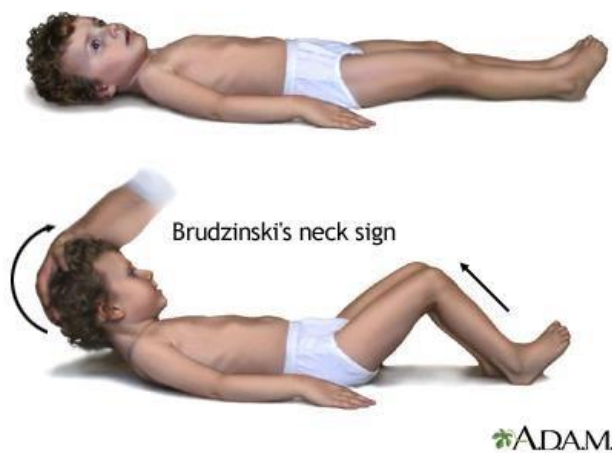

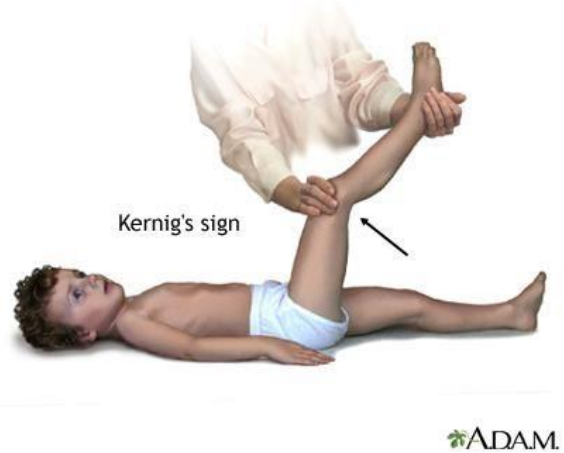Normal Neurological Status

The cranial nerve examination reveals an unremarkable neurological status, characterized by the absence of any discernible external indications of head injury. Notably, there is no evidence of nuchal rigidity, and both Brudzinski and Kernig signs elicit negative responses. Furthermore, there are no observable indications of meningeal irritation.

Brudzinski sign (meningitis):
Patient lies on back.
If Neck flexion ➤ flexion of hip and knees
Then sign positive



Kernig sign (meningitis)
Patient lies on back
If pain upon passive knee
flexion ➤ meningitis



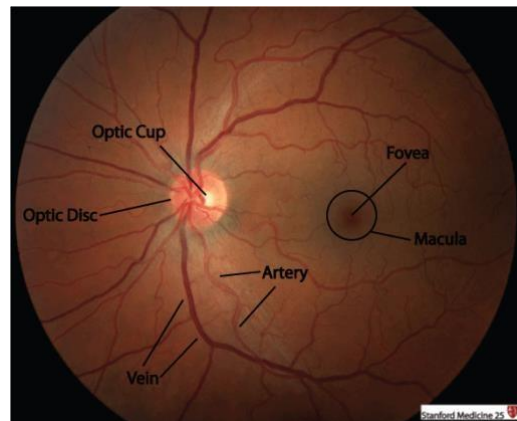
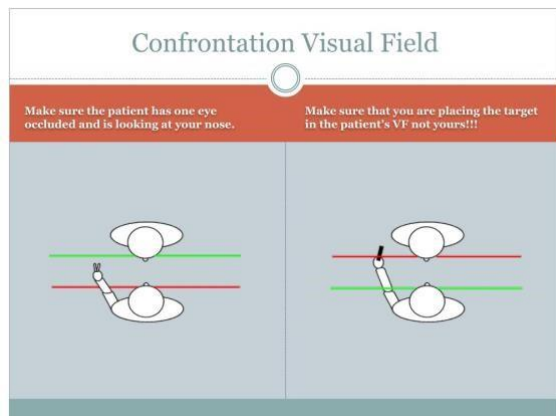
Cranial Nerves Assessment:

I. Olfactory nerve

Regarding the olfactory sense, all tested odours are perceived equally and correctly identified in both nostrils. The patient does not report any pathological alterations in their sense of smell.

II. Optic nerve

Visual examination reveals bilateral visual acuity of 1.0 (20/20). Visual fields are intact upon confrontation testing. Inspection of the optic fundi demonstrates sharply-defined disc edges with a pink hue. The size and regularity of the retinal vessels are within the normal range, and spontaneous venous pulsations are bilaterally present. There is no evidence of abnormal retinal pigmentation.



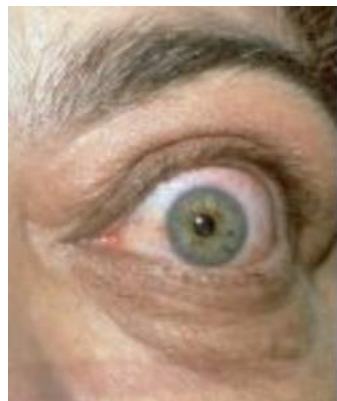III. Oculomotor, IV. Trochlear, and VI. Abducens

Pupil size: Pupils measure 3-4 mm in diameter, exhibiting a round shape and equal size bilaterally. Their responses to both direct and consensual light stimulation are symmetrical.


Additionally, pupils react uniformly to accommodation and convergence in both eyes. Lid and gaze: No evidence of lid retraction, lag, or ptosis is observed. In the primary gaze position, there is no deviation of the eyes.

Extraocular movements: Extraocular movements remain intact in all directions of gaze, without any discernible nystagmus or diplopia.

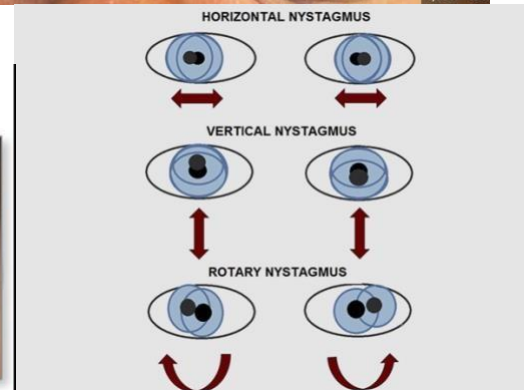
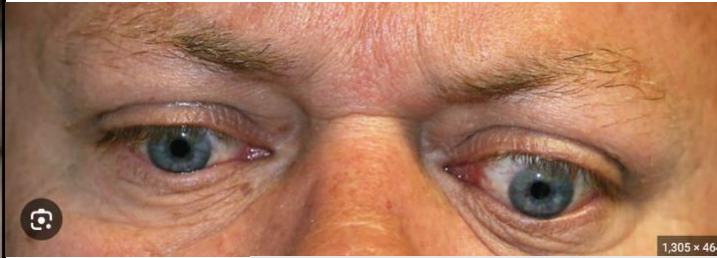Eyelid Retraction



Ptosis (drooping of the eyelid)



Eye lag



Diplopia (Double vision) 7



Note: Primary gaze position is when both eyes are looking straight ahead.

V. Trigeminal (Ophthalmic, Maxillary, Mandibular)

The masticatory muscles demonstrate normal bulk, tone, and strength, exhibiting symmetry on both sides. With the mouth open, there is no deviation of the mandible. Sensory assessment reveals intact and equal touch, pinprick, cold, and heat sensations across all three divisions of the trigeminal nerve on the face. Additionally, the patient correctly recognizes numerals written on the skin of the face within all three divisions of the nerve. The exit points of the supraorbital, maxillary, and mental nerves are not sensitive to pressure, and brisk corneal reflexes can be elicited bilaterally.

VII. Facial Nerve

The face exhibits symmetry at rest, and dynamic facial expressions, including smiling, shutting eyes, and frowning, are performed with equal strength and symmetry on both sides. Taste sensation remains intact on the anterior two-thirds of the tongue. Additionally, brisk corneal reflexes can be elicited bilaterally.

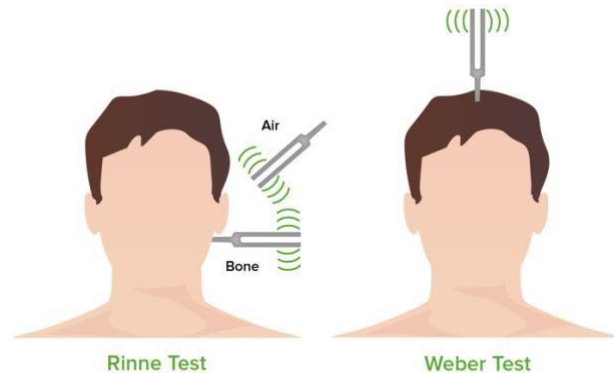
VIII. Vestibulocochlear

Hearing: The patient hears a whispered voice at a distance of fifteen feet (five meters) in each ear, indicating normal hearing. Alternatively, normal hearing is demonstrated by the ability to perceive sound when fingers are rubbed together.

Weber Test: Sound is equally heard in both ears during the Weber test.


Rinne Test: Bilaterally, air conduction is superior to bone conduction in the Rinne test.

Balance and Coordination: No nystagmus is observed. The patient maintains an upright stance in the Romberg position and does not exhibit deviation during the Bárány test. Furthermore, there is no swaying or falling observed when walking with eyes closed.



Romberg position 7

Hearing loss	Rinne test (Conduction)	Weber test (Localization)
None	Air > bone	Midline
Sensorineural		Normal ear
Conductive	Bone > air	Affected ear



IX. Glossopharyngeal X. Vagus

Uvula and Palatal Arches: The uvula is centrally positioned, and the palatal arches display symmetry.

Reflexes: Both the palatal and gag reflexes exhibit moderate intensity and can be elicited on both sides.

Swallowing and Phonation: Swallowing and phonation functions are performed effectively. Taste

Sensation: The patient correctly recognizes tastes and perceives them equally on both sides of the posterior one-third of the tongue.

XI. Accessory

The trapezius and sternocleidomastoid muscles display equal shape, bulk, tone, and strength on both sides. The patient can perform shoulder shrugging and head turning to each side against resistance with normal strength.

XII. Hypoglossal

The protruded tongue is positioned centrally. There is no evidence of atrophy or fasciculation observed in the tongue muscles.

Note: Fasciculation means brief spontaneous contraction.

Motor Function Evaluation:

The skeletal muscles exhibit intact bulk, tone, and strength throughout both the extremities and the trunk. The patient can successfully hold both upper and lower limbs lifted outstretched into the air without any evidence of pronator drift. Additionally, they are capable of walking on both heels and toes. There are no involuntary movements present.

OR

Regarding motor function, there is no pronator drift observed in outstretched arms. Muscle bulk and tone are within the normal range, and bilateral strength is full. No involuntary movements are detected.

Note: Find out name of this stupid table, stupid uni didn't provide it. Stupid.

	Deltoid	Biceps	Triceps	Wrist extension	Finger abduction	Hip flexion	Hip extension	Knee flexion	Knee extension	Ankle flexion	Ankle extension
L	5	5	5	5	5	5	5	5	5	5	5
R	5	5	5	5	5	5	5	5	5	5	5

Sensation Assessment:

The patient demonstrates consistent and equal responses to touch with a small wisp of cotton, pinprick, heat, and cold across all extremities and the trunk bilaterally. Position sense and small joint movement sensation remain intact in all four extremities. The patient accurately recognizes numerals written on the skin covering the entire body. Vibration sensation is equal on both sides, and there are no subjective alterations in sensation reported. Additionally, the patient does not exhibit any extinguishing response to double simultaneous stimulation.

Reflex Examination:

The patient's reflexes are evaluated as follows:

Biceps, patella, and ankle jerks exhibit a medium brisk response (graded as "two plus") bilaterally.

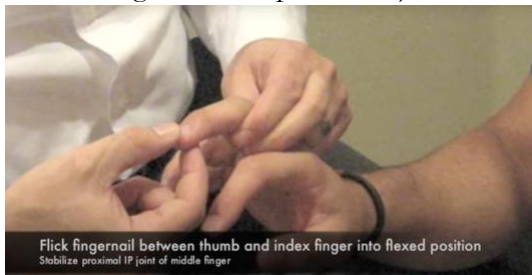Triceps and ulnar jerks display sluggish responses on both sides. Plantar responses are flexor.

The Hoffmann sign can be evoked equally on both sides. No Trömner, Chaddock, Gordon, or Oppenheim signs are present. Bilaterally, abdominal skin and cremaster reflexes are equal and exhibit a medium brisk response. Furthermore, no pathological reflexes, including palmomental, grasping, sucking, or others, are observed.

Hoffman's sign

If adduction of thumb and flexion of index finger upon flicking middle finger nail

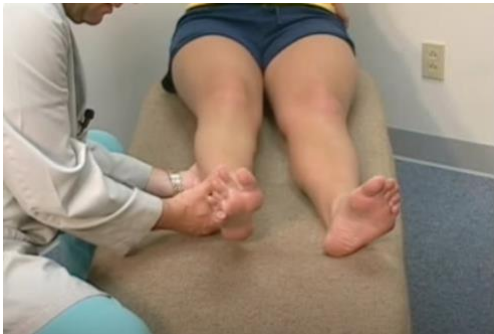Then ⑦ Positive sign (Corticospinal tract dysfunction localised to Cervical segments of spinal cord)



Ref - https://www.youtube.com/watch?v=q_4gpNizwPg&t=17s

Gordon sign

If when calf squeezed toes extend (Babinski response) ⑦
upper motor neuron lesion

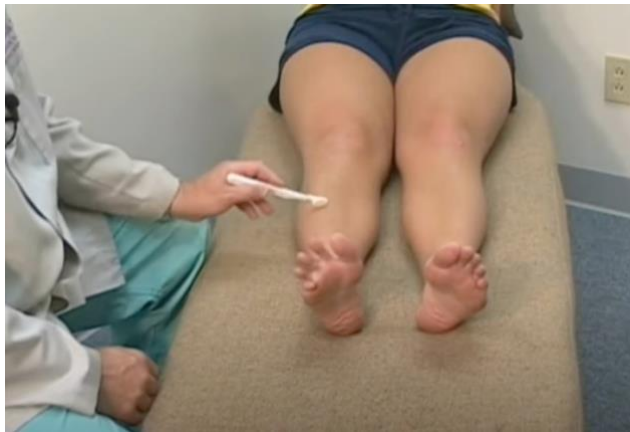

Ref - <https://www.youtube.com/watch?v=dXguDQjYdWs>

Oppenheim sign

If when stroking anterior tibial region toes extend

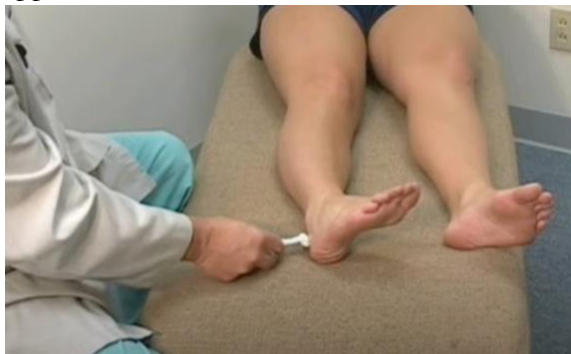⑦ upper motor neuron lesion



Ref- <https://www.youtube.com/watch?v=EiwD6s8dmu4>

Chaddock sign

If when Stroke distal to lateral malleolus along lateral side of foot, toes extend ⑦
upper motor neuron lesion



Ref – <https://www.youtube.com/watch?v=PFoKzgLfzw>

Trömner sign

If after fixing proximal middle phalanx and flicking the volar
Surface of the finger the tip of index finger and thumb flexes. and adducts
⑦ Early sign of pyramidal disease



Ref

https://www.youtube.com/watch?time_continue=4&v=59Tw9hbbAZE&embeds_referring_curi=http%3A%2Fnotes.medicosnotes.com%2F&source_ve_path=MzY4NDIsMzY4NDIsMjg2NjMsMjg2NjY&feature=emb_logo

Coordination Assessment:

The patient's coordination is evaluated as follows:

Posture is normal. Gait is steady with regular steps, base, arm swing, and turning. Heel and toe walking are performed without any issues. No deviation is noted in the Bárány test or blind walking. Tandem gait remains normal, even when one of the patient's eyes is closed. Both the finger-to-nose and heel-knee-shin tests are performed accurately. There are no signs of rebound or dysdiadochokinesis. No abnormal or extraneous movements are observed.

Rebound is when the arm shoots back up after tapping it.



Ref - <https://www.youtube.com/watch?v=SiZLBQPHGk&t=4s>

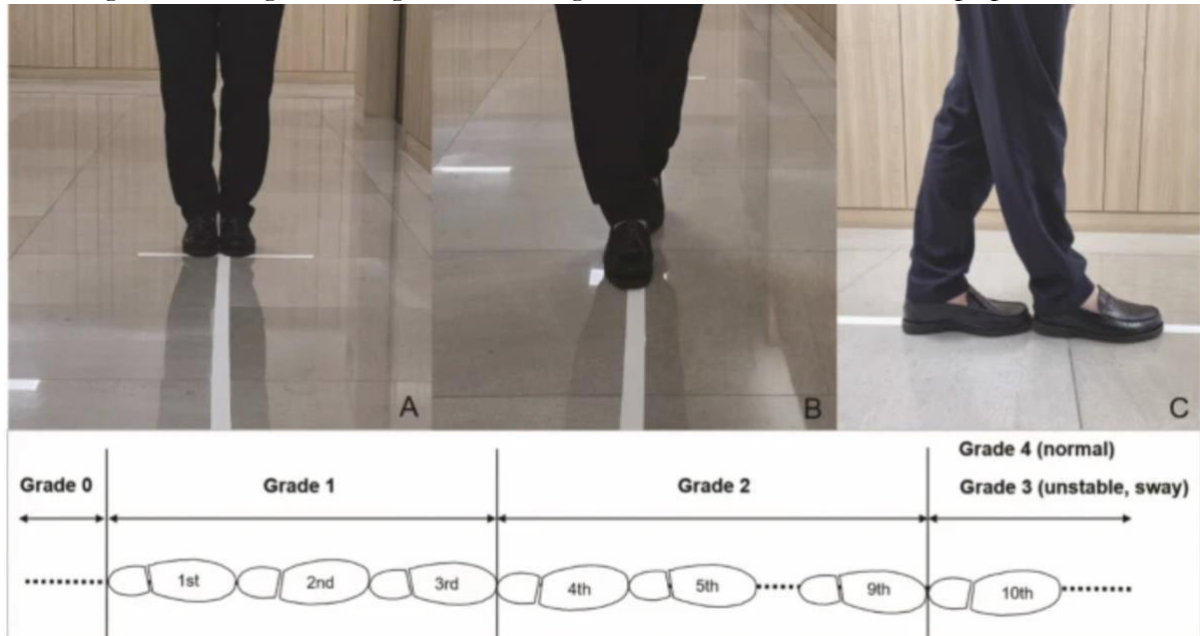
Dysdiadochokinesis

Inability to perform rapid alternating movements.



Ref - <https://www.youtube.com/watch?v=2EiZqnmXWyAY>

Tandem gait is walking in a straight line and is graded based on number of steps patient can take.



Autonomic Function and Mental State Assessment:

In terms of autonomic functions:

Normal sudomotor and vasomotor activity is noted, and there are no reported issues with sphincter function.

Assessment of mental state reveals that the patient is fully alert and capable of accurately recalling personal data. They demonstrate orientation in both space and time. Additionally, their speech is clear and fluent, accompanied by proficient abilities in repetition, comprehension, and naming. The patient also successfully recalls 3 out of 3 objects after a 5-minute interval, indicative of intact short-term memory.

Note: Sudomotor means autonomic control of sweat gland activity